

## Double symmetrical aortic arch in a Czechoslovakian wolfdog – surgical treatment and health assessment four years after treatment: a case report

P. SKRZYPCZAK, A. PIATEK\*, J. BIEZYNSKI, Z. KIELBOWICZ

Faculty of Veterinary Medicine, University of Environmental and Life Sciences in Wrocław, Wrocław, Poland

\*Corresponding author: anita.piatek@up.wroc.pl

**ABSTRACT:** The paper describes a double symmetrical aortic arch in a dog trapping the oesophagus. Thoracotomy was performed in the fourth inter-costal space under general, isoflurane-maintained, anaesthesia. Cutting of the arterial ligament failed to free the oesophagus. Dissection of further vascular structures revealed the left and right aortic arches to be of similar diameter. A vascular clamp was put on the left arch for 10 min, while the patient's cardiovascular parameters were monitored. The lack of significant cardio-respiratory symptoms indicated the necessity of ligating and cutting the left aortic arch. Removal of additional tissue from the region of the cut on the left arch completely released the oesophagus which was continuously monitored by video-oesophagoscopy. The chest was closed according to a standard thoraco-surgical procedure. The cutting of the left aortic arch and the release of the surrounding tissue restored the normal position of the oesophagus. After surgery, the animal was returned to its owners in a very good condition. Control examination showed complete amelioration of clinical symptoms and subsequent normal development of the dog. Intra-operative clamping of the left aortic arch with simultaneous monitoring by oesophagoscopy ensured a positive outcome of the surgery of the intra-operatively diagnosed double aortic arch.

**Keywords:** symmetrical double aortic arch; dog; vascular ring

A “vascular ring” is a developmental anomaly of the aortic arch, in which the oesophagus or the trachea are partially or completely surrounded by major blood vessels. In humans, different types of aortic rings constitute 0.7–1.3% of congenital heart disorders (Skalski and Religa 2003). There is no precise statistical information on the incidence of this disorder in animals. The most common vascular ring type in dogs with clinical symptoms – 95% of all cases of vascular ring – is the persistent right aortic arch with left ligamentum arteriosum (PRAA) (Buchanan 2004). PRAA occurs mostly in large breeds of dogs (92% cases occur in dogs over 15 kg), such as German shepherds, Irish setters, or Great Danes (Patterson 1968; Van den Ingh and Van der Linde-Sipman 1974; Shires and Liu 1981).

The double aortic arch is the most common type of vascular ring in humans, and its symptoms result from trapping and constriction of the oesophagus and trachea (Skalski and Religa 2003). The first description of the double aortic arch anomaly was provided by Hommel in 1737 (Skalski and Religa 2003), and the first successful surgery was performed by Gross in 1945 (Gross 1945).

Only a few published reports regarding the double aortic arch in dogs are available (Aultman et al. 1980; Martin et al. 1983; Findji and Degueurce 1999; Ricardo et al. 2001; Vianna and Krahwinkel 2004; Du Plessis et al. 2006; Moonan et al. 2007). It constitutes 1% of all vascular ring anomalies diagnosed in dogs and is even less frequent in other animal species such as Siamese cats (Yarim et al.

1999), talapoin monkeys (Still et al. 1979) and lions (Goldin and Lambrechts 1999).

### Case description

A 10-week-old Czechoslovakian wolfdog was referred to the Department of Surgery, Faculty of Veterinary Medicine, University of Environmental and Life Sciences in Wrocław, Poland, with a suspicion of a vascular ring anomaly. Anamnesis confirmed the regular incidence of regurgitation, appearing soon after meals. Clinical symptoms, which were rare during the first days of the dog's life, rapidly intensified after weaning. Moreover, the owner noticed problems such as wheezing during breathing, which intensified after meals. Clinical examination revealed malnutrition without signs of dehydration. Despite its normal appetite, the dog was smaller than its littermates. Its body temperature was normal. Auscultation of the heart and lungs showed no abnormalities. Haematological examination revealed slight hypoproteinaemia, hypoalbuminaemia and neutropaenia. The basic biochemical indicators (ALT, AST, ALP, urea, creatinine, glucose) were within the physiological range. The thoracic radiogram showed a distinct, air-filled oesophagus located cranially to the heart. Contrast radiography revealed a constriction of the oesophagus over the base of the heart and its sac-like dilatation in the pre-cardiac area. Oesophagoscopy using a videoendoscope confirmed the drastic constriction of the thoracic part of the oesophagus. Moreover, large pulsating vessels could be seen on the right side of the oesophageal wall. Persistent right aortic arch with left ligamentum arteriosum (PRAA) was preliminarily diagnosed based on the clinical examination, contrast radiography and oesophagoscopy.

The dog was pre-medicated with medetomidine (10 mg/kg; Cepetor, Scanvet) and midazolam (Midanium, Polfa) administered intramuscularly at 0.1 mg/kg. Induction to anaesthesia was performed using propofol (Plofed 1%, Polfa, Poland; dose was adjusted based on the clinical effect). The general anaesthesia was maintained with isoflurane (Foran, Abbot 1.5–2.5 vol%). Mechanical ventilation was performed during the whole procedure. Intra-operative analgesia was maintained using fentanyl (Fentanyl, Polfa, Poland), administered intravenously at 2 mg/kg at 30-minute-intervals.

Additionally, inter-costal local analgesia of five inter-costal spaces (Th 2–6) was performed pre-surgery, using 0.5% bupivacaine (Bupivacainum Hydrochloricum 0.5%, Polfa, Poland Th 2–6). The vascular ring was accessed by left thoracotomy of the fourth inter-costal space. Opening of the pericardium revealed a normally developed left aortic arch and, arising from it, ligamentum arteriosum which ended in the pulmonary artery. For better visualisation of the deeper-situated structures and in order to confirm that the ligamentum arteriosum actually participated in the formation of the vascular ring, two ligatures were put on the ligamentum arteriosum which was then cut along the middle of its length. Unfortunately, endoscopy, performed immediately after this step of surgery, did not reveal any changes. Moreover, insertion of the endoscope into the constricted part of the oesophagus caused trachea dysfunction followed by respiratory failure clearly seen on the capnograph. Removal of the endoscope solved the respiratory problems and confirmed the initial diagnosis of a double aortic arch. It was decided that the structures surrounding the dilated, pre-cardiac part of the oesophagus would be prepared first. This step confirmed that the oesophagus was situated between two large pulsating vessels of a similar diameter. Palpation revealed that they were connected and formed a uniform vascular ring structure. Because one of the vessels was the left aortic arch, intra-operative diagnosis of a double aortic arch anomaly was made. Detailed examination of the two arches revealed that they were of the same size. Because no other vessels apart from ligamentum arteriosum arose from the left aortic arch, it was decided to cut the left aortic arch. Following precise preparation of the surrounding structures, vascular clamps were put on the left aortic arch for 10 min (Figure 1A). In the meantime, cardiovascular system parameters were monitored continuously and carefully. Attempts were made at assessing the degree of dilatation of the right aortic arch by palpation. No significant changes in the cardiovascular system were found: only a 10% decrease in heart rate and a 15% drop in blood pressure were observed (measured oscillometrically). Importantly, there were no significant changes in the diameter of the right aortic arch. Two ligatures (Eticon cardiovascular 2.0 material) were placed on the exposed part of the left aortic arch, followed by incision of the vessel between them. The stumps were protected

doi: 10.17221/274/2015-VETMED

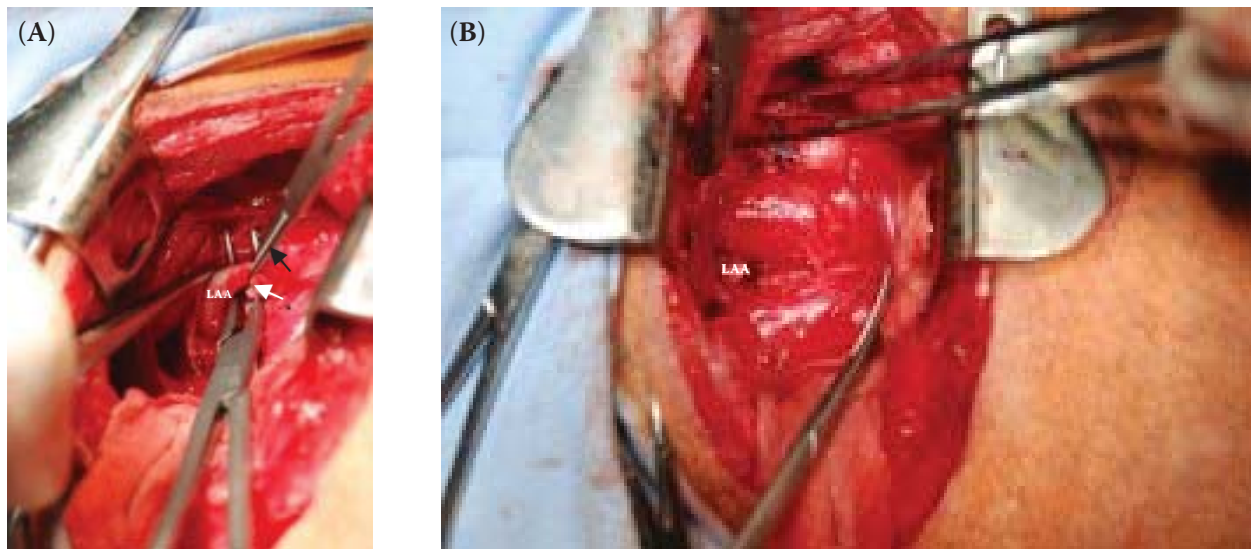


Figure 1. (A) Clamping of the left aortic arch (LAA). (B) Released oesophagus after cutting the left aortic arch. Black arrow = vascular clamp, white arrow = ligated ligamentum arteriosum

with extra stitches. Subsequent preparation of the surrounding structures released the oesophagus completely (Figure 1B), which was confirmed by videoendoscopy.

A thoracic catheter was placed and secured in the fourth inter-costal space using 2.0 nylon stitches. Closure of the chest was initiated with the fastening together of ribs IV and V using 1/0 nylon threads. Then, the inter-costal muscles and the chest-covering muscles were stitched together with running polidioksanian 3/0 stitch. The hypodermis was stitched using running stitch made with poliglecaprone threads and the skin using simple interrupted stitch of 3/0 nylon. Having achieved wound tightness, the air was removed from the pleural cavity, restoring the negative pressure inside it. Inhalation was applied until complete restoration of normal ventilation.

Post-operative analgesia was achieved using buprenorphine at 0.015 mg/kg (Bunondol, Polfa, Poland), administered at 8-hour-intervals for three days and with carprofen at 2 mg/kg (Rimadyl, Pfizer) administered at 12-hour-intervals for seven days. The dog also received amoxicillin (Betamox, Scanvet) and metoclopramide (Metaklopramidum 0.5%, Polpharma). The dog was discharged three days after surgery in a very good condition. The owner was informed about the necessity to feed the dog in vertical position with pulpy food during the following two weeks. Ten days after thoracotomy the stitches were removed, and the dog began to feed in a horizontal position with solid food. It was

subject to check-up one month, three months and 12 months post-surgery.

## DISCUSSION AND CONCLUSIONS

Phylogenetically, the right aortic arch is typical of birds, and the double aortic arch is characteristic of reptiles. Ontogenetic development of the main arteries departing from the heart is closely associated with the appearance and disappearance of brachial arch arteries. Fundamental changes in the configuration of symmetrical aortic arches involve the fourth aortic arch. During physiological development, the right fourth aortic arch with a part of the dorsal aorta form the right sub-clavian artery. However, the left fourth aortic arch extends and, together with the corresponding part of the dorsal aorta, forms the main aortic arch. In cases of double aortic arch, the right, fourth aortic arch does not disappear. In human cases of double aortic arch, the cervical and sub-clavian arteries arise separately from each aortic arch (Skalski and Religa 2003). The ascending aorta is divided in two arches encircling the trachea and oesophagus. This disorder may assume different forms. Both aortic arches may have the same diameter, the left aortic arch may be the dominant one, or, as occurs in 75% of cases, the right arch is larger (Han et al. 1993). It is probable that this type also predominates in dogs. Among 52 cases of persistent right aortic arch, in six cases the left aortic arch was

arthritic (Buchanan 2004). Thus, it can be assumed that in double aortic arch cases, depending on the anomaly type (asymmetrical or symmetrical), two different kinds of embryological disorders are involved. Symmetrical double aortic arch develops from persistent right and left fourth aortic arches. Asymmetrical double aortic arch consists of two vessels, one of which is hypoplastic. Most often, the left aortic arch is the arthritic one. In this type of anomaly, the hypoplastic left aortic arch probably develops from the second or third left aortic arch (Cornali et al. 1976).

The aetiology of the vascular ring anomaly in animals is still unclear. In humans, a genetic factor has been confirmed: at least some aortic arch anomalies are associated with microdeletion syndrome of gene 22q11.2 on chromosome 22 (Restivo et al. 2006). In animals, the genetic origin of this syndrome is also accepted, although there is no literature information on the involvement of this gene in the dog disorders. In addition to the genetic factors, in dogs and cats, teratogenic factors, infectious diseases affecting the mother in the first period of pregnancy, as well as vitamin A deficiency, are thought to play roles (Patterson 1968). In the cases described in the literature, the defect was found in three German shepherds (Martin et al. 1983; Findji and Degueurce 1999; Moonan et al. 2007), two crossbreed dogs (Findji and Degueurce 1999; Vianna and Krahwinkel 2004) and a Beagle (Du Plessis et al. 2006). In the case described here, the dog was of a young breed obtained by crossing the Carpathian wolf with the German shepherd. The latter breed is predisposed to pathologies involving various types of vascular rings.

Complete vascular rings in children are usually responsible for respiratory symptoms. Compression of the trachea may lead to serious damage of cartilage and sometimes extensive tracheo- and bronchomalacia (Skalski and Religa 2003). So far, there are no descriptions of serious respiratory distress due to the presence of vascular rings in animals. The major clinical symptoms in dogs are related to oesophageal obstruction; pathognomonic symptoms of oesophageal stenosis include repeated vomiting of undigested food, which can occur during food intake, immediately after its consumption, or on rare occasions, after a longer period of time. These are clearly the consequences of the oesophagus constriction and the lack of passage of food content into the stomach. A very important

diagnostic feature is the animal's age. As in many other congenital heart defects, the first symptoms appear in very young animals. Their time of appearance is usually closely correlated with the transition from liquid milk diet to solid food, which in dogs and cats usually happens at the age of 3–4 weeks.

The introduction of very simple diagnostics in the form of X-ray with barite oesophagography in 1936 by Kommerell enabled *in vivo* diagnosis of a vascular ring (Kommerell 1936). Food regurgitation, especially in young animals, is always an indication for X-ray examination of the neck and chest. In these images the oesophagus is apparent as a structure widening in the cranial direction and filled with air and food. In the dorso-ventral projection it is sometimes possible to identify the descending aorta on the right side of the oesophagus in animals with persistent right-sided aortic arch. Contrast examination of the oesophagus can determine the extent of its widening in the pre-cardiac section of the thoracic part, which in some cases may extend up to the cervical part with characteristic constriction at the base of the heart, where the contrast agent accumulates. It is strongly recommended to repeat the contrast barite radiography four months after surgery in order to assess the degree of oesophagus dilation.

Endoscopy is performed to rule out other causes of oesophagus obstruction and to assess the prevalence of erosions and ulcerations. The throbbing on the right side of the oesophagus, observed in this study, indicated the likelihood of a persistent right aortic arch. Intra-operative oesophagoscopy performed using a videoendoscope is particularly recommended for surgical correction of vascular rings. Placing the tip of the endoscope at the oesophagus constriction greatly facilitates the identification of anatomical structures involved in the formation of the ring. In addition, this technique makes it possible to control the effect of the widening of the oesophageal lumen after cutting of the vascular structures involved in its formation. It also offers the possibility of precise preparation of the oesophagus-surrounding tissue, thus allowing for the widest oesophagus lumen.

In human medicine, angiography, magnetic resonance imaging or computer tomography are performed in order to differentiate between the types of vascular ring disorders. In animals, this type of diagnosis is very rarely used. Angiography does not reveal the ligamentum arteriosum, because blood



doi: 10.17221/274/2015-VETMED

does not flow through it, but shows other abnormal vessels. In 2008, we reported the application of CT angiography using a computer to diagnose persistent right aortic arch with left arterial ligament in a dog (Pownder and Scrivani 2008). Since these tests are expensive and require specialist equipment, usually only intra-operative evaluation of the vascular ring type is done.

Despite the early implementation of appropriate diagnostics, it is advisable to carry out identification of the arteries which supply the head and the descending aorta in the operative field. Usually, an attempt at clamping the place which is likely to release the ring shows whether the forced flow left after the cutting of the vessel will be sufficient. These considerations primarily concern the symmetrical double aortic arch. In our case, clamping of the left arch for 10 min did not cause any problems in the flow of blood to the descending aorta and subsequently in the peripheral circulation. In cases where there is a distinct size difference between the right and left arch, the decision to cut the hypoplastic arch is usually obvious. When both arches have similar dimensions, cutting of the left one seems more advisable, since developmentally it is more likely that it is a pathology. Besides the classic left-sided thoracotomy, ligation and cutting of the left aortic arch are technically easier. The stumps of the aortic arch should be carefully closed, and, subsequently, they should be freed from the surrounding tissue, with the widest possible margin. Such release combined with extensive mobilisation of the cut vessel is very helpful and even necessary to achieve complete decompression of the constricted oesophagus. In most cases, the effect of surgery can be observed in the first days after the release of the aortic ring.

In all cases of vascular ring anomalies, the animal's owners should be informed about all aspects of treatment and aspects that require the exercise of caution. In case of double aortic arch, beside the prognosis associated with pre-stenotic enlargement of the oesophagus, there is also a need to take into account hypertension associated with ligation of one of the arches. The patient, therefore, should at least initially regularly undergo sonographic examination of the heart in order to identify any potential post-surgery left ventricular failures. Endoscopic examination performed three months after surgery showed full patency of the oesophagus with a distinct enlargement in its pre-cardiac

section. Despite these changes, after the dog was returned to the owners after surgery, they did not notice a single incident of food regurgitation. Also, the weight of the animal significantly increased. Before surgery, the weight of the dog was 7.5 kg, 30% lower in comparison with other dogs from the same litter. In the control examination one month after the surgery the dog weighed 12.4 kg, and the average weight of the other puppies from the litter was 13.1 kg. Clinical examination one year after the surgery did not reveal any abnormalities of the gastrointestinal tract. Further, the dog was ranked excellent in a junior class dog show. After four years, the dog was subject to radiographic examination in connection with an injury of the left hind limb. The dog's overall condition was found to be very good; its appetite was excellent without any problems with swallowing, vomiting occurred only occasionally (1–2 times a year), weight was 35.2 kg, and there was a lack of any health problems except for the limb injury. Control echocardiography showed no abnormalities. Endoscopic examination, except for the previously observed pre-cardiac enlargement of the oesophagus, did not show any changes.

Owing to its rarity in animals, the double aortic arch is rarely mentioned in the literature; there is even less information on the long-term survival after surgical correction of the defect. According to our knowledge only two of the reported cases in dogs survived the surgical intervention and were returned to their owners in good condition (Vianna and Krahwinkel 2004; Moonan et al. 2007). In other cases, one dog was euthanised before the end of surgery (Martin 1983), one died 30 min after surgery (Findji and Degueurce 1999) and one on the second day post-surgery (Du Plessis 2006). Here, we have described the third case of treatment of a dog with double aortic arch and the second successful correction of a symmetrical aortic arch. We believe that the diagnostic and operational procedures described here will help to improve the effectiveness of surgical treatment of this defect, and that the long-term follow-up will provide valuable clinical information.

## REFERENCES

Aultman SH, Chambers JN, Vestre WA (1980): Double aortic arch and persistent right aortic arch in two littermates:

- surgical treatment. *Journal of the American Animal Hospital Association* 16, 533–536.
- Buchanan JW (2004): Tracheal signs and associated vascular anomalies in dogs with persistent right aortic arch. *Journal of Veterinary Internal Medicine* 18, 510–514.
- Cornali M, Reginato E, Azzolina G (1976): Cervical aortic arch and a new type of double aortic arch. *British Heart Journal* 38, 993–996.
- Du Plessis CJ, Keller N, Joubert KE (2006): Symmetrical double aortic arch in a beagle puppy. *Journal of Small Animal Practice* 47, 31–33.
- Findji L, Degueurce C (1999): Symmetrical double aortic arch in a dog. *Veterinary Record* 145, 465–466.
- Goldin JP, Lambrechts NE (1999): Double aortic arch and persistent left vena cava in a white lion cub (*Panthera leo*). *Journal of Zoo and Wildlife Medicine* 30, 145–150.
- Gross RE (1945): Surgical relief for tracheal obstruction from a vascular ring. *The New England Journal of Medicine* 233, 586–590.
- Han MT, Hall DG, Manche A, Rittenhouse EA (1993): Double aortic arch causing tracheoesophageal compression. *The American Journal of Surgery* 165, 628–631.
- Kommerell B (1936): Verlagerung der Oesophagus durch eine abnorm verlaufende Arteria subclavia dextra (*Arteria lusoria*). *Fortschritte auf dem Gebiete der Röntgenstrahlen und der Nuklearmedizin* 54, 590.
- Martin DG, Ferguson EW, Gunnels RD, Robinowitz M, Toft JD (1983): Double aortic arch in a dog. *Journal of the American Veterinary Medical Association* 183, 697–699.
- Moonan N, Mootoo NF, Mahler SP (2007): Double aortic arch with a hypoplastic left arch and patent ductus arteriosus in a dog. *Journal of Veterinary Cardiology* 9, 59–61.
- Patterson DF (1968): Epidemiologic and genetic studies of congenital heart disease in dog. *Circulation Research* 23, 171–173.
- Pownder S, Scrivani PV (2008): Non-selective computed tomography angiography of a vascular ring anomaly in a dog. *Journal of Veterinary Cardiology* 10, 125–128.
- Restivo A, Sarkozy A, Digilio MC (2006): 22q11 deletion syndrome: a review of some developmental biology aspects of the cardiovascular system. *Journal of Cardiovascular Medicine* 7, 77–85.
- Ricardo C, Augusto A, Canavese S, Marcos A, Ticona E, Fernandes M, Rita M, Singareti F (2001): Double aortic arch in a dog (*Canis familiaris*): a case report. *Anatomia, Histologia, Embryologia* 30, 379–381.
- Shires PK, Liu W (1981): Persistent right aortic arch in dogs: a long-term follow-up after surgical correction. *Journal of the American Animal Hospital Association* 17, 773–775.
- Skalski JH, Religa Z (eds) (2003): *Children's Cardiac Surgery* (in Polish). Scientific Publisher "Silesia", Katowice. 361–373.
- Still HF, Bond MG, Bullock BC (1979): Double aortic arch in a talapoin monkey (*Miopithecus talapoin*). *Veterinary Pathology* 16, 266–267.
- Van den Ingh TS, Van der Linde-Sipman JS (1974): Vascular rings in the dog. *Journal of the American Veterinary Medical Association* 164, 939–939.
- Vianna ML, Krahwinkel Jr DJ (2004): Double aortic arch in a dog. *Journal of the American Veterinary Medical Association* 225, 1222–1224.
- Yarim M, Gultiken ME, Ozturk S, Sahal M, Bumin A (1999): Double aortic arch in a Siamese cat. *Veterinary Pathology* 36, 340–341.

Received: December 17, 2015

Accepted after corrections: March 1, 2017